

Accommodation Amplitude After Lens Refilling With Injectable Silicone by Sealing the Capsule With a Plug in Primates

Okihiro Nishi, MD; Kayo Nishi, MD

Objective: To restore accommodation in primate eyes by refilling the lens capsule with injectable silicone compounds.

Materials and Methods: Eight eyes of 8 monkeys (*Macaca fascicularis*) were treated by the lens refilling procedure. To prevent leakage of the injected liquid silicone before it polymerized in the capsule in vivo, a silicone plug for sealing the capsular opening was developed. After endocapsular phacoemulsification following an upper minicircular capsulorhexis, the plug was introduced into the capsulorhexis opening. A silicone mixture was injected into the capsular bag through the delivery tube of the plug. Automated refractometry was performed 1 week and 3 months after surgery. Accommodation amplitude was determined as the difference between the refractions before and 1 hour after topical application of 4% pilocarpine chloride.

Results: Five of 8 eyes could be refilled. In 4 of 5 eyes,

refraction could be measured. Accommodation amplitude ranged from 1.0 to 4.5 diopters, with a mean of 2.3 ± 1.3 diopters (8.0 ± 2.0 preoperative values). At 3-month examination, thick posterior capsule opacification precluded refractometry in all eyes.

Conclusions: The lens refilling procedure with the use of a silicone plug for sealing the capsular opening was feasible in primate eyes. The accommodation amplitude attained was a small fraction of the value before surgery. This may result from the loss of so-called intracapsular accommodation, ie, active participation of lens fiber cells in accommodation. However, since the obtained accommodation may be sufficient for near vision after cataract surgery, this lens refilling procedure warrants further study. Elucidation of the mechanism of intracapsular accommodation may also be necessary.

Arch Ophthalmol. 1998;116:1358-1361

REFILLING the lens capsule after endocapsular phacoemulsification aspiration through a minicircular capsulorhexis while preserving capsular integrity offers the potential to restore ocular accommodation.¹⁻⁸ There are a few reports confirming this possibility. Haefliger et al⁴ observed shallowing of the anterior chamber after lens refilling after 4% pilocarpine chloride was injected into the anterior chamber, suggesting restoration of accommodation. We could confirm a mean accommodation amplitude of 4.6 ± 0.5 diopters (D) in young cynomolgus monkey eyes after they were refilled by means of an inflatable endocapsular balloon.⁷ Sakka et al⁸ also confirmed some accommodation in 2 monkey eyes with the use of our procedure.

Because of the technical complexity of the procedure with an inflatable balloon, we developed a new direct lens refilling procedure⁹: a silicone plug for seal-

ing the capsular opening proved to be effective for preventing leakage of the injected liquid silicone before it polymerized within the capsular bag of a pig cadaver or rabbit eye. In this study, we refilled primate lenses by the same procedure, and the results are reported here.

RESULTS

Five of 8 lenses could be refilled. Failure in 3 lenses was the result of capsular rupture. In 2 lenses, rupture occurred during insertion of the capsular plug because of a large discrepancy in size between the CCC and capsular plug. In the remaining lens, rupture occurred during injection of the silicone mixture.

This article is also available on our Web site: www.ama-assn.org/ophth.

From the Nishi Eye Hospital, Osaka, Japan.

MATERIALS AND METHODS

PREPARATION BEFORE LENS REFILLING

Eight lenses of 8 young crab-eating monkeys (*Macaca fascicularis*) were used for the study. Two to 3 months before the lens capsule was refilled, sector iridectomies at the 6- and 12-o'clock positions were performed to facilitate the lens refilling procedure and automated refractometry after surgery. Refraction and accommodation amplitude (see below) were determined at least 1 month after iridectomy. The animals were housed at the Yaotsu Breeding Laboratory (Japan EDM Inc, Gifu, Japan), where the experiments were performed. The monkeys were treated humanely according to the principles of the Primate Society of Japan.¹⁰

CAPSULAR PLUG FOR SEALING THE CAPSULAR OPENING

A capsular plug⁹ for sealing the capsular opening to prevent leakage of the injected silicone was made from silicone. The plug consisted of a thin delivery tube (outer diameter, 0.365 mm; inner diameter, 0.305 mm) with a disk-shaped silicone double plate, 0.38 mm thick, fixed to the end of the delivery tube. Between the 2 plates, there was a soft silicone gel that attached the 2 plates. The inner lumen of the delivery tube was filled with a soft, cured silicone gel to prevent reflux of the injected filling material.

LENS REFILLING PROCEDURE

After the monkey was anesthetized with ketamine hydrochloride (5 mg/kg) and xylazine hydrochloride (2 mg/kg), the pupil was maximally dilated. Then, a 3-mm incision was made at the limbus by means of a disposable 3-mm keratome. After the anterior chamber was filled with a viscoelastic substance, a prick was made in the capsule at the upper region near the corneal incision with a disposable 27-gauge needle. From the capsular incision, a small continuous circular capsulorhexis (CCC) 1.5 to 1.8 mm in diameter then was completed with the use of a capsulorhexis forceps.

After endocapsular phacoemulsification was performed with a 0.8-mm thin tip (Alcon Co, Fort Worth, Tex), lens epithelial cells were removed as thoroughly as possible by aspiration. The capsular plug then was inserted in such a manner that the soft silicone gel between the 2 plates

blocked the capsular opening. After the anterior chamber was filled with a viscoelastic substance, a small amount was injected into the capsular bag to inflate only the CCC region to facilitate plug insertion. The top of the capsular plug was entirely inserted into the capsular bag, while the CCC opening was widened by hooking its edge with a blunt Bonn iris hook from the side port, similar to putting a tire on the wheel. The viscoelastic was removed from the capsular bag by aspiration with a Simcoe cannula. The cannula was introduced through the capsular opening, within which the thin delivery tube of the capsular plug and the cannula were now contained. After the viscoelastic substance was removed from the capsular bag, the upper plate of the plug was brought outside the capsular opening by pulling with the tire-wheel maneuver described above, so that the soft silicone gel between the 2 plates blocked the CCC opening.

Thereafter, 0.2 mL of a mixture of 2 liquid silicone compounds, polymethylsiloxane as the main component and hydrogen polysiloxane as a cross-linking agent, was injected with an odontology syringe (Citoject, Bayer Dental Nippon, Osaka, Japan) through the delivery tube. After the capsular bag was filled with the silicone mixture, the delivery tube was cut at its root. Then, tight corneal sutures were used for closure.

One percent atropine sulfate ointment was applied in the conjunctival sack at the end of the surgery to maintain zonular relaxation.

POSTOPERATIVE EXAMINATIONS

After lens refilling, all monkeys underwent slitlamp examination and automated refractometry while they were anesthetized, as described above, 1 week and 3 months postoperatively.

Refraction was measured in the anesthetized animals by means of an automated refractometer (Auto-Kerato-Refractometer KR-3000, Topcon Co, Tokyo, Japan) before and 1 hour after topical application of 4% pilocarpine to alter the lens shape. Refraction was determined as an equivalent value. Accommodation amplitude was determined as the difference between these 2 refraction values. Each measurement was performed 5 times by 1 of 3 masked persons, and the median value for each animal was used to calculate the overall mean value.

One monkey was killed 6 months postoperatively by injection of succinylcholine chloride after anesthesia. The refilled lens was then examined histopathologically.

However, the CCC opening appeared to have already been damaged during insertion of the capsular bag.

SLITLAMP FINDINGS

At 1-week examination, the whole lens capsule was clear in 3 eyes, and migrating cells and flare in the anterior chamber were few and slight. Refraction could be measured by the automated refractometer. Two of 5 eyes showed fibrinous exudation on the anterior lens capsule (**Figure 1**). Fibrinous exudation in 1 of these 2 eyes in which refraction could be measured despite the condition had disappeared at 3-month examination. The other eye eventually progressed to phthisis bulbi because of en-

dophthalmitis. These monkeys were the first to undergo surgery. Thereafter, we disinfected the eye more strictly before surgery, as in surgery on humans. As a result, changes in refraction could be measured in 4 eyes 1 week after surgery (**Table**). However, at 3 months postoperatively, anterior and posterior capsule opacification precluded refractometry in all 4 eyes. The anterior capsule was relatively clear, sporadically showing a fine fibrotic type of opacification (Figure 1).

AMPLITUDE OF ACCOMMODATION

The preoperative refraction before pilocarpine application ranged from 0 to -2.0 D, and those 1 hour after such

Preoperative and Postoperative Refractions and Accommodation Amplitude in Lenses Refilled With Injectable Silicone: Change in Refraction Before and 1 Hour After Topical Application of 4% Pilocarpine

Monkey No./Age, y	Preoperative Refractions, Diopters (D)			Postoperative Refractions, D		
	Before	After	Change	Before	After	Change
1/13	-2.00	-13.25	11.25	+5.00	+0.50	4.50
2/5	-1.00	-6.75	5.75	+7.25	+6.25	1.00
3/5	0	-7.50	7.50	+5.00	+3.00	2.00
4/6	-1.75	-9.25	7.50	+8.50	+7.00	1.50
Mean ± SD	-1.2 ± 0.8	-9.2 ± 2.5	8.0 ± 2.0	+6.4 ± 1.5	+4.2 ± 0.6	2.3 ± 1.3

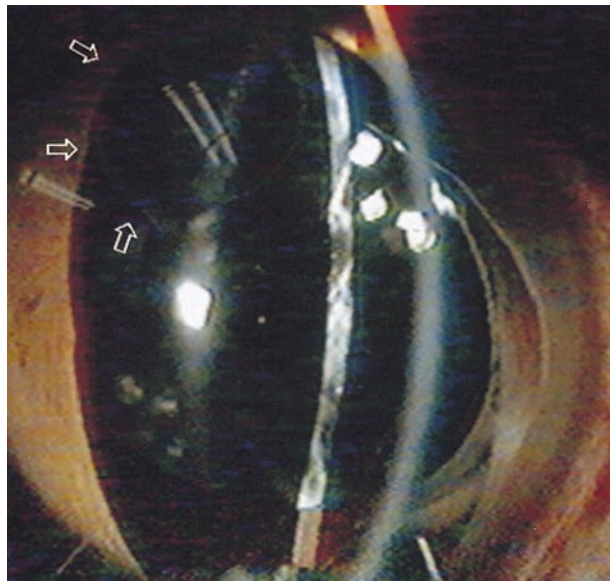


Figure 1. Slitlamp finding of the refilled lens of a primate eye 3 months after surgery. Fibrotic anterior capsule opacification developed and precluded refractometry. The posterior capsule is relatively clear. Note the optically empty silicone within the capsular bag. The arrows indicate the capsular plug.

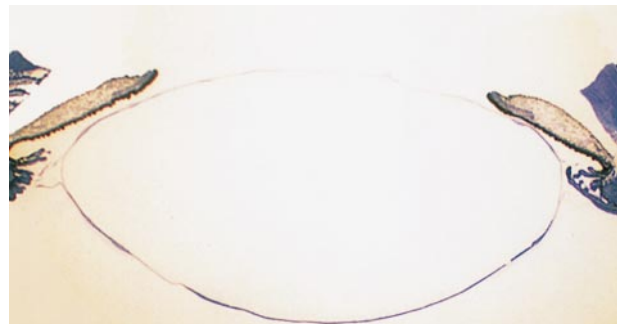

Figure 2. Histopathological section of a refilled lens capsule from the monkey eye shown in Figure 1, 6 months after surgery. The section was cut horizontally from the middle of the resected specimen. Note the lens epithelial cells that migrated onto the posterior capsule (toluidine blue, original magnification $\times 9$).

application ranged from -6.75 to -13.25 D. Postoperative refractions before pilocarpine application ranged from +5.0 to +8.5 D, and those 1 hour after application ranged from +0.5 to +7.0 D. Accordingly, the preoperative accommodation amplitude ranged from 5.75 to 11.25 D with a mean (\pm SD) of 8.0 ± 2.0 D, while the postoperative accommodation amplitude ranged from 1 to 4.5 D with a mean of 2.3 ± 1.3 D (Table).

HISTOPATHOLOGICAL EXAMINATION

The lens capsule was well stretched and showed that its integrity was obviously preserved. Thick posterior capsule opacification could be observed (**Figure 2**).

COMMENT

We performed refractometry 1 week after surgery, because our previous study^{7,9} showed that posterior capsule opacification occurred rapidly in the refilled lens capsule, precluding refractometry. As a result, changes in refraction in the refilled lenses could be measured in 4 lenses, excluding 1 that developed fibrinous reaction. At 3-month examination, refraction could not be mea-

sured in any of the eyes because of increasing posterior capsule opacification, obviously showing that prevention of this opacification is an essential issue to be solved in lens refilling. In this regard, ultrasonographic biometry may provide useful additional data regarding posterior capsule opacification in future studies.

Postoperative refraction will be primarily determined by refractive index of the injected silicone with a fixed certain value and anterior capsule curvature that depends on the degree of filling. The more tautly the capsule is filled, the steeper the anterior capsule curvature, thus the greater the refraction. Filling degree, however, also influences accommodation amplitude. The optimal accommodation amplitude will be obtained by filling the capsule with 60% to 70% of bag volume with silicone compounds, according to our previous study.⁹ Thus, postoperative refraction and accommodation amplitude both depend on filling degree, yet they comprise 2 reciprocally counterbalancing variables in lens refilling on the premise that filling material with only 1 specific refractive index is available. In other words, obtaining the optimal accommodation amplitude in lens refilling can be achieved at the price of achieving emmetropia. In this study, we attempted to obtain optimal accommodation by filling the lens capsule to 60% to 70% of bag volume. As a result, a mean accommodation amplitude of 2.3 ± 1.3 D could be obtained at the price of hyperopic shift in postoperative refraction with a mean value of +6.4 D (Table). Postoperative emmetropia may be achieved by intraoperative and postoperative refractive corneal surgery or phakic intraocular lens. Therefore, refractive surgery may have great implications in lens refilling.

Although we refilled the lens capsule to obtain apparently optimal accommodation amplitude, we obtained only a small fraction of the amplitude before surgery. Similar results were also obtained in our previous study⁷ involving lenses refilled with inflatable endocapsular balloon. We think this may be caused by the loss of intracapsular accommodation, ie, the active participation of lens fiber cells in accommodation.¹¹ On the basis of his mathematical calculations, Gullstrand postulated that the change in the shape of the lens during accommodation could be realized only by the shifting of lens fiber cells against each other.

As circumstantial evidence, some findings indicate the existence of intracapsular accommodation.^{11,12} The fiber itself does not shift, but rather the contents of the fibers shift during accommodation. Metabolism in lens fiber cells is similar to that in muscle contraction. Contractile and cytoskeletal filaments such as actin, vimentin, and tubulin have been detected in the intracellular matrix of lens fiber cells. The adenosine triphosphate-adenosine diphosphate ratio falls after fiber shifting, but it is restored rapidly, similar to that in muscle. If there is such intracapsular accommodation, the full accommodation amplitude cannot be restored simply by refilling the lens capsule with an artificial material, although 3 D of accommodation might be clinically sufficient for near vision after surgery.

The rapidly developing posterior capsule opacification is another problem to be solved. The use of YAG laser capsulotomy may annul the accommodation attained. Furthermore, the question of whether a useful degree of accommodation can be obtained in a presbyopic eye by lens refilling remains unanswered. Using high-resolution ultrasonographic biometry, Bacsuklin et al¹³ recently showed that ciliary muscles contracted during accommodation even in presbyopic eyes. However, the extent to which loss of capsular elasticity affects restoration of accommodation remains unknown. The procedure should be tested in an aged primate eye.

In conclusion, refilling the lens capsule with injectable silicone in monkey eyes was feasible. The obtained accommodation amplitude was a small fraction of the

value before surgery. This may have resulted from the loss of so-called intracapsular accommodation. Nevertheless, this lens refilling procedure warrants further investigation, since 3 D of accommodation might be sufficient for near vision after surgery. Posterior capsule opacification must be prevented, because capsulotomy might annul the accommodation attained.

Accepted for publication June 26, 1998.

Reprints: Okihiko Nishi, MD, Nishi Eye Hospital, 4-14-26, Nakamichi, Higashinari-ku, Osaka 537, Japan (e-mail: okihiko@nishi.ganka.or.jp).

REFERENCES

1. Kessler J. Experiments in refilling the lens. *Arch Ophthalmol.* 1964;71:412-417.
2. Agarwal LP, Narsimhan EC, Mohan M. Experimental lens refilling. *Orient Arch Ophthalmol.* 1967;5:205-212.
3. Parel J-M, Gelender H, Treffers WF, Norton EWD. Phaco-ersatz. *Graefes Arch Clin Exp Ophthalmol.* 1986;224:165-173.
4. Haeffliger E, Parel J-M, Fantès F, et al. Accommodation of an endocapsular silicone lens (phaco-ersatz) in the nonhuman primate. *Ophthalmology.* 1987;94:471-477.
5. Gindi JJ, Wan WL, Schanzlin DJ. Endocapsular cataract surgery. *Cataract.* 1985;2:6-10.
6. Nishi O. Refilling the lens of the rabbit eye after endocapsular cataract surgery. *Folia Ophthalmol.* 1987;38:1615-1618.
7. Nishi O, Nakai Y, Yamada Y, Mizumoto Y. Amplitudes of accommodation of primate lenses refilled with two types of inflatable endocapsular balloons. *Arch Ophthalmol.* 1993;111:1677-1684.
8. Sakka Y, Hara T, Yamada Y, Hara T, Hayashi F. Accommodation in primate eyes after implantaion of refilled endocapsular balloon. *Am J Ophthalmol.* 1996;121:210-212.
9. Nishi O, Nishi K, Mano C, Ichihara M, Honda T. Controlling the capsular shape in lens refilling. *Arch Ophthalmol.* 1997;115:507-510.
10. Primate Society of Japan. Guiding principles for primates. *Primate Res.* 1986;2:111-113.
11. Kleefeld O. Beiträge zum intrakapsulären Akkommodations mechanismus. *Doc Ophthalmol Adv Ophthalmol.* 1956;10:132-168.
12. Hockwin O. Biochemie der Linse: ein Rückblick auf thematische und methodische Entwicklungen, ein Ausblick auf zukünftige Forschungen. *Klin Monatsbl Augenheilkd.* 1993;202:544-551.
13. Bacsuklin A, Gast R, Bergmann U, Guthaff R. Ultrasehallbiomikroskopische Darstellung der akkommodativen Konfigurationsänderungen des presbyopen Ziliarkörpers. *Ophthalmologie.* 1996;93:199-203.

IN OTHER AMA JOURNALS

JAMA

Telomerase and the Aging Cell: Implications for Human Health

Michael Fossel, MD, PhD

Recent research has shown that inserting a gene for the protein component of telomerase into senescent human cells reextends their telomeres to lengths typical of young cells, and the cells then display all the other identifiable characteristics of young, healthy cells. This advance not only suggests that telomeres are the central timing mechanism for cellular aging, but also demonstrates that such a mechanism can be reset, extending the replicative life span of such cells and resulting in markers of gene expression typical of "younger" (ie, early passage) cells without the hallmarks of malignant transformation. It is now possible to explore the fundamental cellular mechanisms underlying human aging, clarifying the role played by replicative senescence. By implication, we may soon be able to determine the extent to which the major causes of death and disability in aging populations in developed countries—cancer, atherosclerosis, osteoarthritis, macular degeneration, and Alzheimer dementia—are attributable to such fundamental mechanisms. If they are amenable to prevention or treatment by alteration of cellular senescence, the clinical implications have few historic precedents. (1998;279:1732-1735)

Reprints: Michael Fossel, MD, PhD, 9464 Conservation Ave, Ada, MI 49301 (e-mail: Mfossel@aol.com).